

Nurse *Achieve*



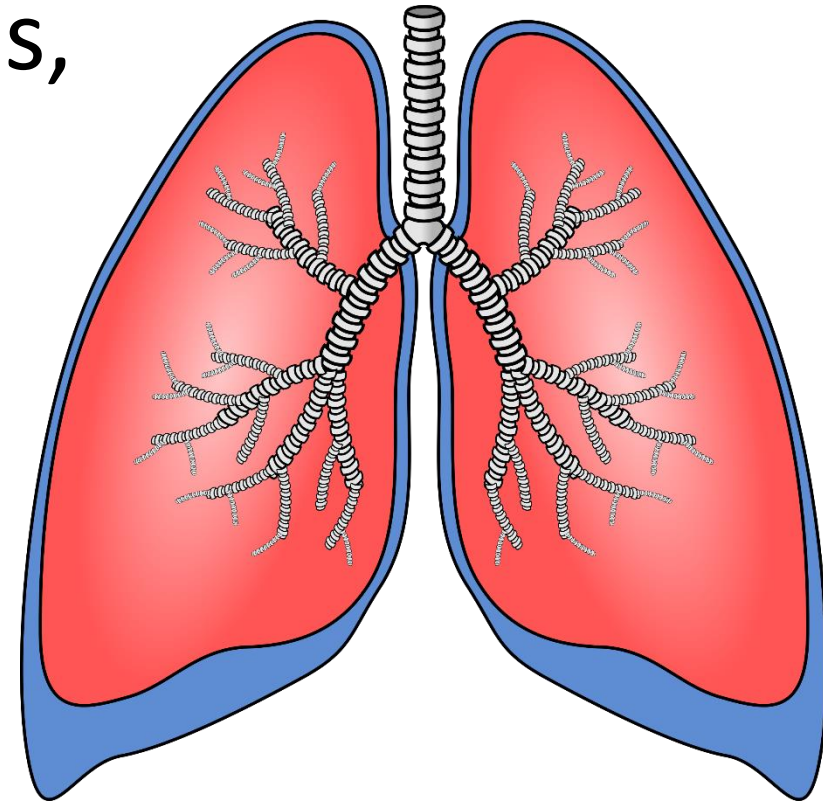
CHEST INJURIES

TABLE OF CONTENTS

- [Objectives](#)
- [Chest and respiratory structures](#)
- [Rib fractures](#)
- [Pneumothorax](#)
- [Hemothorax](#)
- [Chest tube drainage](#)
- [Summary](#)
- [References](#)

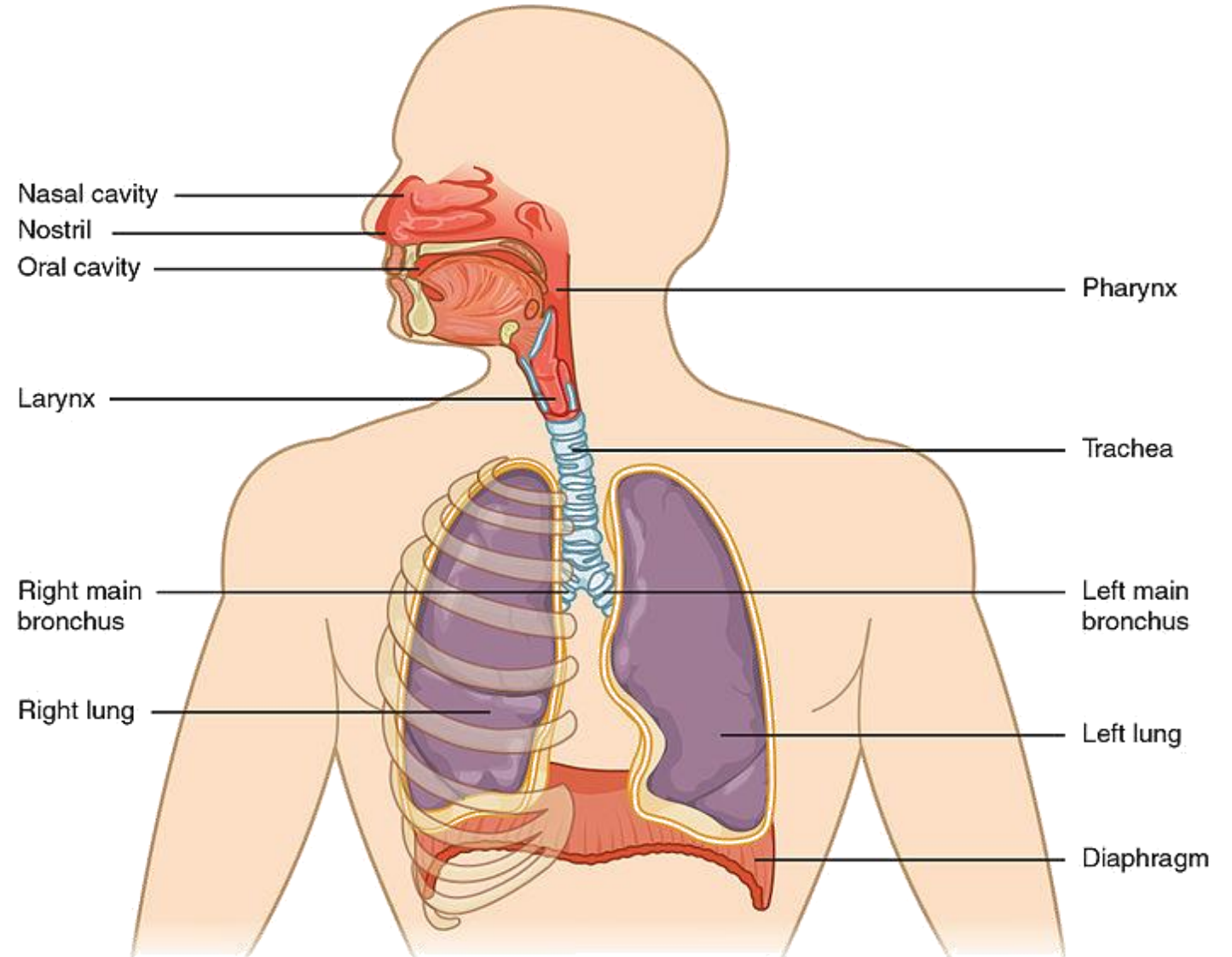
OBJECTIVES

- Understand the anatomy of the chest and the structures involved in breathing
- Explain and understand rib fractures, pneumothorax and hemothorax
- Recognize the priority nursing interventions involved in treating chest injuries



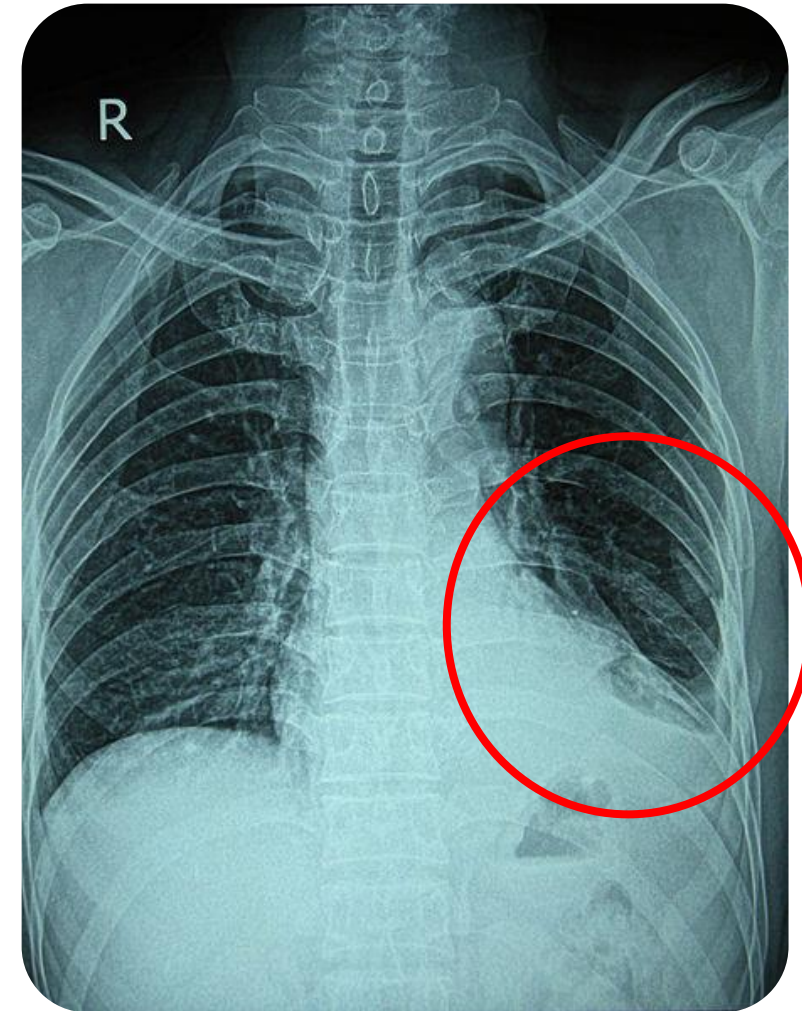
THE CHEST

- **Upper Respiratory Tract:** Nose, sinuses, pharynx, larynx and epiglottis
- **Lower Respiratory Tract:** Trachea, bronchi, bronchioles, alveoli and lungs
- **Accessory Muscles**
- **Diaphragm**
- **Ribcage**



RIB FRACTURE

- Most common chest wall injury
- Typically due to blunt trauma to the chest
- Manifestations of a rib fracture include pain (especially during inspiration/coughing) and bruising at the site of injury
- Often resolves spontaneously and the main focus is pain management (NSAIDs and analgesics) to allow for effective breathing
- Diagnosis confirmed via chest x-ray



RIB FRACTURE

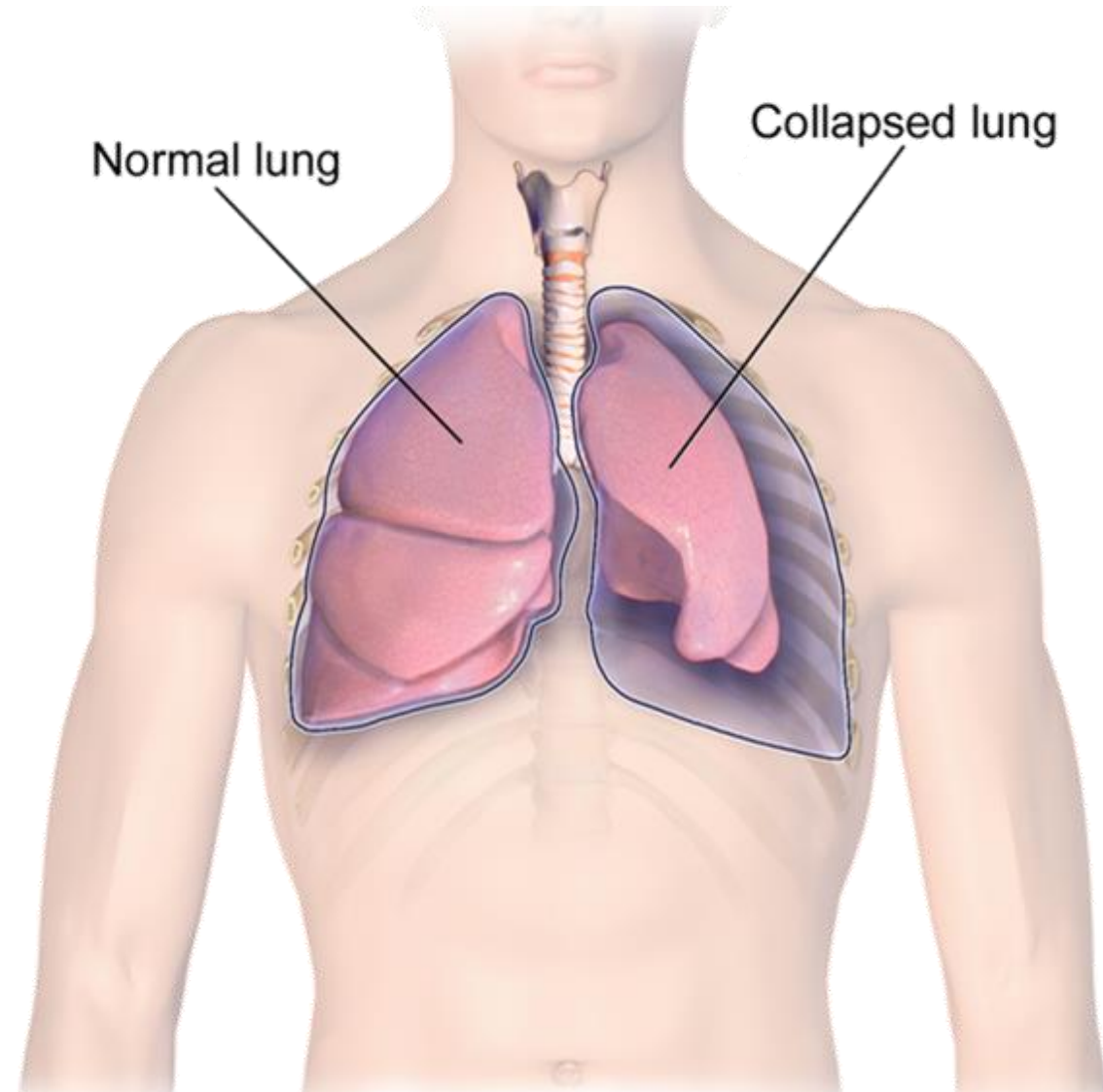
- Flail chest (free-floating section of chest wall) can occur if multiple consecutive ribs are fractured
- Displaced fractured ribs can penetrate the pleura and result in a pneumothorax or hemothorax

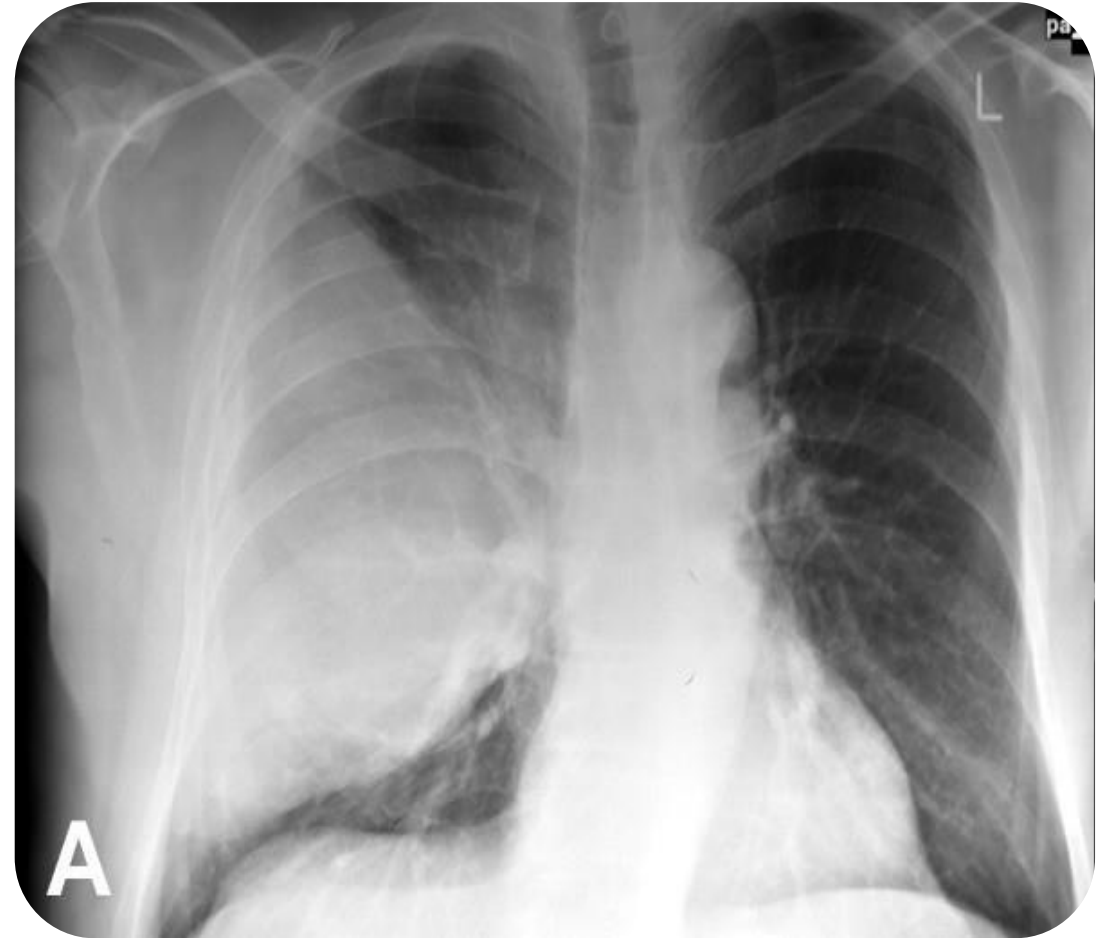

Image: Courtesy of Somshekar Ganti ([License](#))

PNEUMOTHORAX

- Occurs when air accumulates in the pleural space
- Can occur due to trauma, lung disease, or spontaneously
- Various types of pneumothorax
- Diagnosis via chest x-ray



PNEUMOTHORAX

Pneumothorax

Open

(Sucking Chest Wound)

- Result of penetrating trauma or impalement
- Chest cavity exposed to outside air
- Significant hypoventilation as lung collapses

Closed

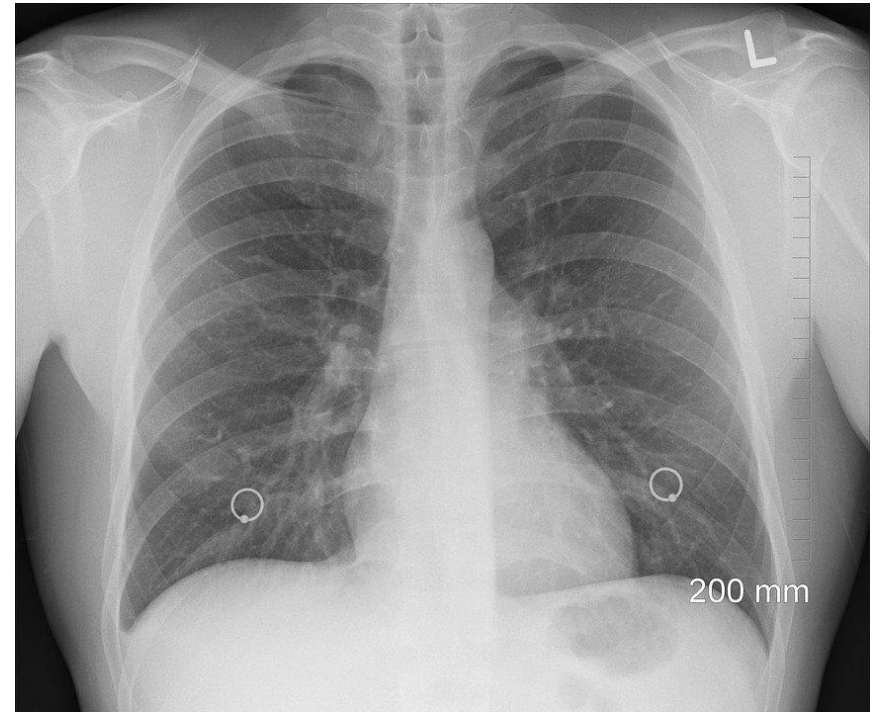
- Chest wall is intact, no communication between chest cavity and outside air
- Caused by an existing lung injury (e.g. cancer)

Tension

- Air enters and gets trapped in pleural space
- Increased pressure causes compression of the lung, heart, and mediastinum

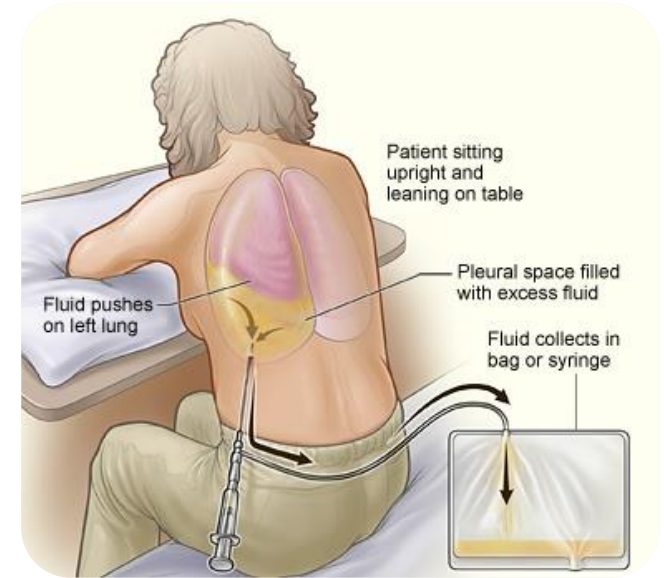
PNEUMOTHORAX

- Chest tubes with drainage typically used to allow lungs to re-expand
- Needle aspiration can be used to remove air in the pleural space
- Invasive interventions not needed when client is stable with minimal air/fluid accumulation; provide supportive measures as the condition resolves spontaneously



HEMOTHORAX

- Blood in the pleural space
- Occurs due to trauma, invasive procedures, or underlying conditions
- Causes dyspnea, dullness to percussion, decreased hemoglobin and may cause shock
- Diagnosis through lab tests (e.g. hemoglobin, arterial blood gases), chest x-ray, and signs and symptoms
- Thoracentesis or thoracotomy with chest tube drainage to remove blood and relieve pressure in pleural space
- Empyema: purulent fluid in the pleural space

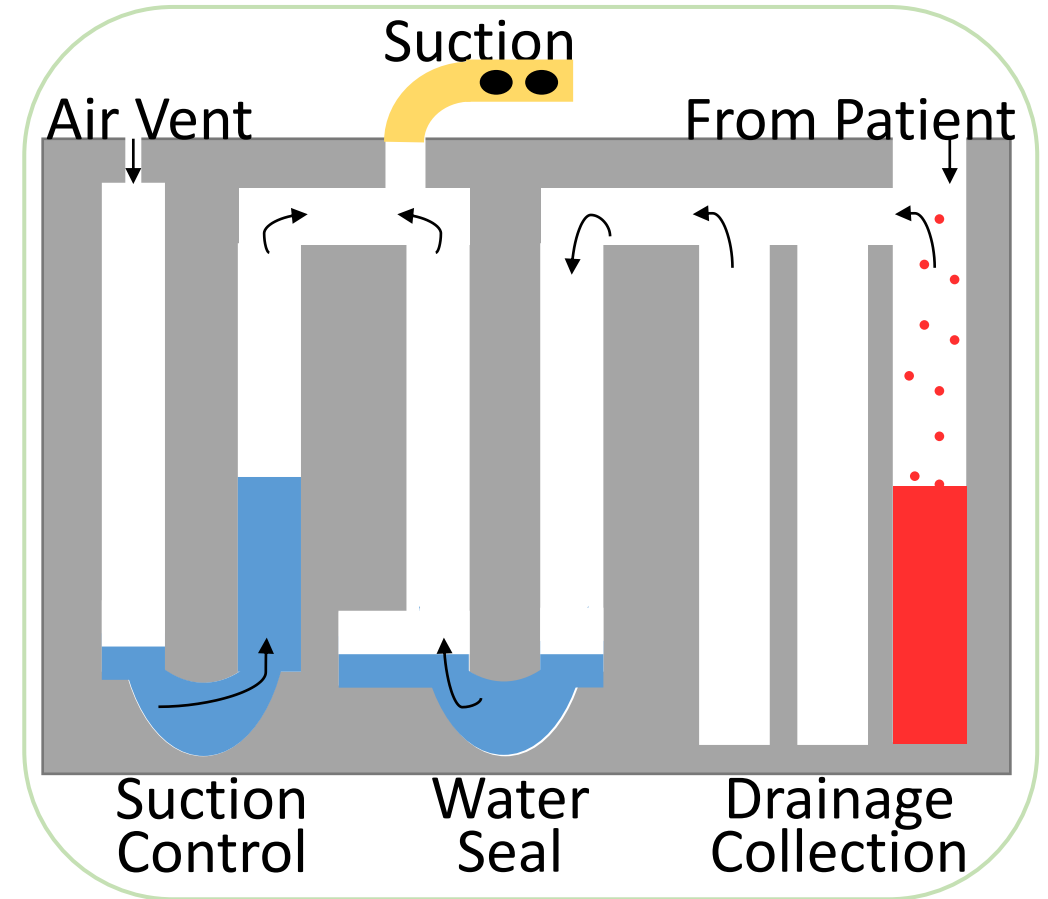


CHEST TUBE DRAINAGE

- Chest tubes are surgically placed, and air-tight dressings are used to cover the puncture wounds
- Proper tube placement is confirmed by chest x-ray
- A water seal drainage system is often used to prevent air/fluid from moving back into the chest cavity
- Typically not emptied unless it is full to prevent risks of contamination or malfunction
- The system has three chambers for drainage collection, water seal and suction control

CHEST TUBE DRAINAGE

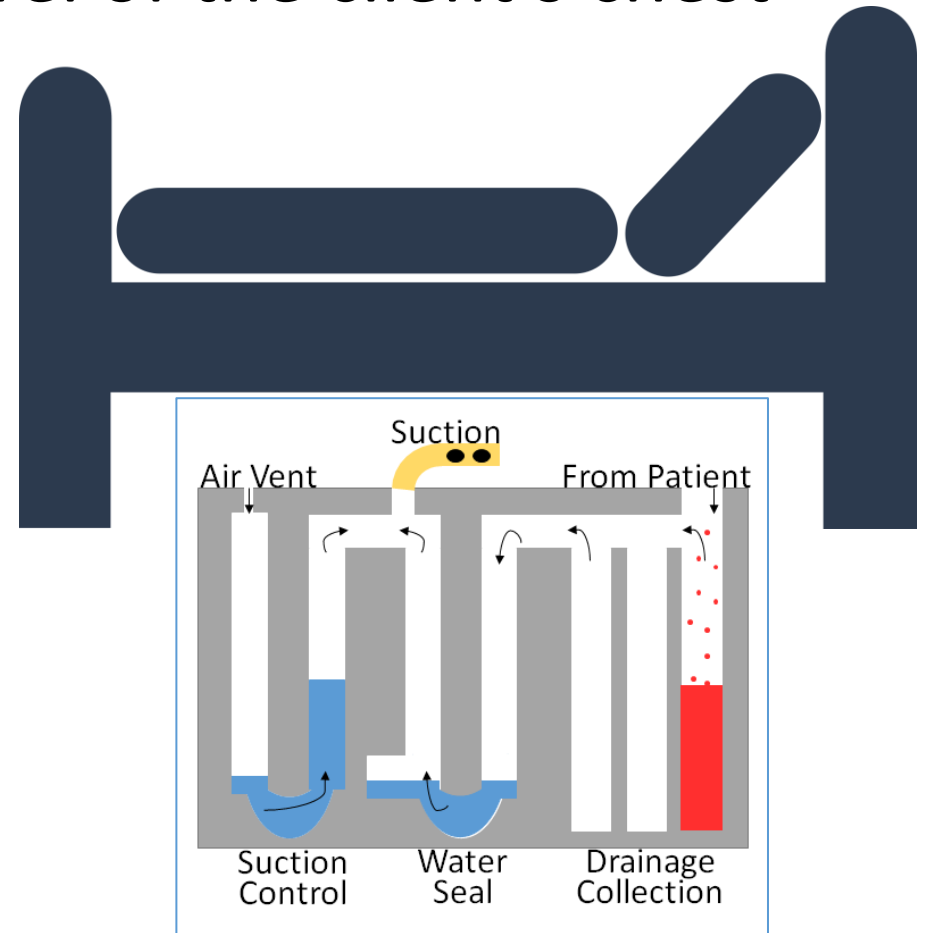
- Fluid and air collected from the client enters the chamber
- Air moves into the water seal and causes intermittent bubbling
- Continuous bubbling indicates an air leak (physician should be notified)
- The system is connected to external suction (e.g. on the wall)



CHEST TUBE DRAINAGE

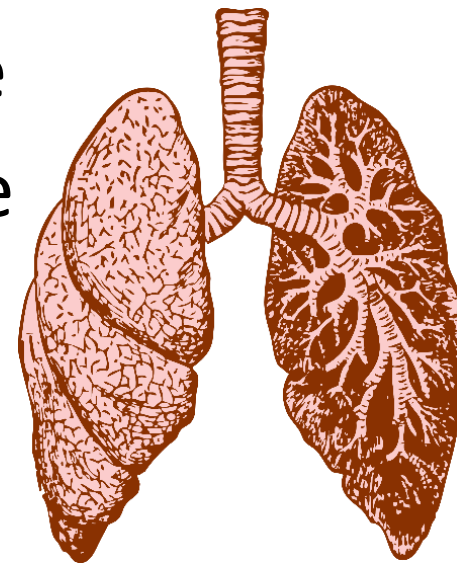Management of the Drainage System

- Keep the drainage system below the level of the client's chest
- Ensure all tubes are connected and check patency of the tubes
- Check the water level and check for bubbling (should be intermittent)
- Check and document the color, characteristics and amount of fluid
- Monitor client status and manage pain from puncture wounds



SUMMARY

- Rib fractures are the most common chest injury and typically resolve on their own with pain management interventions
- Pneumothorax occurs when air enters the pleural space and can be classified as an open (sucking chest wound), closed or tension pneumothorax
- Hemothorax occurs when blood enters the pleural space
- The priority nursing intervention is to maintain adequate respiratory function and cardiac output
- Interventions typically include chest tube drainage and thoracentesis or thoracotomy



REFERENCES

1. Bauldoff G, Gubrud P, Carno M. (2019). *LeMone and Burke's Medical-Surgical Nursing: Clinical Reasoning in Patient Care*. (7th edition). Pearson.
2. Harding MM, Kwong J, Roberts D, Hagler D, Reinisch C. (2019). *Lewis's Medical-Surgical Nursing: Assessment and Management of Clinical Problems*, (11th edition). Mosby.
3. Ignatavicius DD, Workman ML, Rebar CR. (2021). *Medical-Surgical Nursing: Concepts for Interprofessional Collaborative Care*. (10th edition). Elsevier.
4. Jarvis C, Eckhardt A. (2020). *Physical examination & health assessment*. (8th edition). Elsevier.
5. Perry A, Potter P, Ostendorf W. (2021). *Clinical Nursing Skills and Techniques*. (10th edition). Mosby.